

PHARMACOLOGY AND TOXICOLOGY

A New Property of Endogenous Immunostimulator Taftsin

T. S. Pavlov and G. E. Samonina

Translated from *Byulleten' Eksperimental'noi Biologii i Meditsiny*, Vol. 138, No. 8, pp. 185-187, August, 2004

Original article submitted January 19, 2004

Taftsin, an endogenous peptide immunostimulator, exhibits also high antiulcer activity. In a dose of 0.6 $\mu\text{mol/kg}$ Taftsin decreases the area of ulcerative lesions in albino rats on various models of ulceration.

Key Words: *Taftsin; stomach ulcer; regulatory peptides*

The search for antiulcer preparations yields a number of new synthetic peptide compounds. Synthetic hybrid peptides Semax and Selank are fragments of natural proteins stabilized by attachment of the Pro-Gly-Pro residue to the C-terminal region. Semax contains fragment 4-7 of adrenocorticotrophic hormone. Selank includes a tetrapeptide fragment of immunoglobulin G named Taftsin. These peptides produce various effects on the organism [1,2,4].

The immunostimulator Taftsin (Thr-Lys-Pro-Arg) has phagocytotic, antitumor, and antimicrobial properties [9]. The preparation modulates activity of the central nervous system [3] and blood coagulation system [5].

Here we studied the effect of Taftsin on ulceration and healing of ulcers caused by homeostatic disorders in the gastric mucosa (GM) using various models of ulceration.

MATERIALS AND METHODS

The formation of ethanol ulcers and stress-induced (water immersion) ulcers is primarily mediated by peripheral and central mechanisms, respectively. The effect of Taftsin on the formation and healing of ulcers was studied using acetate model of ulceration.

Experiments were performed on male outbred albino rats (ethanol and acetate ulcers) and Wistar rats. The animals were deprived of food 1 day before the experiment and housed in cages with grid floor to prevent coprophagia. Experimental and control animals intraperitoneally received the test peptides and physiological saline, respectively.

On the model of ethanol ulceration, ethanol (96%, 1 ml/200 g) was administered through a gastric tube. The animals received intraperitoneal injections of peptides or physiological saline 1 h before ethanol administration. The rats were killed with ether 1 h after treatment. Lesions in GM develop 10 min after ethanol administration and become more pronounced 1 h after treatment.

Ulceration was produced by water-immersion immobilization stress. The animals were fixed on the back to a special grid (crucifixion) and immersed in water (16°C) vertically up to a lower level of the sternum. The test peptides or physiological saline were injected intraperitoneally 1 h before stress. The rats were decapitated after 3-h stress. Spot lesions in GM were considered as stress ulcers [7].

Acetate ulcers were assayed as described elsewhere [8]. Experiments were performed on male outbred albino rats weighing 200-350 g. The abdominal cavity was opened under ether anesthesia. Glacial acetic acid was applied to the serous surface of the pylorus with a cotton tampon (diameter 0.5 mm) for 15 sec. After application the surface of the stomach was dried with filter paper, and the abdominal cavity was sutured.

Department of Human and Animals Physiology, Biological Faculty, M. V. Lomonosov Moscow State University. **Address for correspondence:** samonina@pisem.net. Samonina G. E.

Ulcer on the inner surface of the stomach developed 1 day after application, attained maximum size on day 4, and then healed.

We performed 2 series of experiments. In series I, the test preparations were injected over the first 3 days after application. In series II, the test preparations were administered for 3 days starting from day 4 after surgery (period of extensive ulceration). Administration of the preparation within the first 3 days after acid application to the serosa primarily affects ulcer formation, while treatment in the period of extensive ulceration modulates ulcer healing.

The area of ulcers (mm²) was measured with an ocular micrometer to estimate the severity of lesions. We calculated the total and mean areas of lesions in each stomach. The results were analyzed by LSD test.

Taftsin was synthesized at the Institute of Molecular Genetics (Russian Academy of Sciences). The peptide was dissolved in physiological saline immediately before the experiment and administered in a dose of 0.6 μ mol/kg (1 ml/200 g).

RESULTS

Severe hemorrhages and erosions of considerable length were formed on GM 1 h after ethanol administration. In control animals, the mean area of ulcers 1 h after ulcerogenic exposure was 35.76 mm² (14.4-88.3 mm²). Intraperitoneal injection of Taftsin decreased the mean area of ulcerative lesions to 7.31 mm² (21.1% of the control). Therefore, Taftsin demonstrated a protective effect during ulceration mediated by peripheral mechanisms (Fig. 1).

The mean area of ulcers in control rats 3 h after water-immersion stress was 0.47 mm² (0.06-2.00 mm²). In rats treated with Taftsin the area of ulcerative lesions was 0.3 mm², which did not differ from the control. Hence, Taftsin had no protective activity in stress-induced ulceration realized via central mechanisms (Fig. 1).

Administration of ethanol and exposure to stress are followed by the formation of surface erosions and hemorrhages in the stomach. These lesions rapidly develop and regenerate 3-5 h after treatment. Lesions of GM produced by acetate are morphologically and temporally similar to those observed in peptic ulcer disease. The ulcer formed after acid application represent a crater of different depth with clear-cut boundaries. Lesions of GM were characterized by the presence of inflammatory exudate (necrosis) and undifferentiated granulated tissue. We revealed obliteration of submucosal and muscle structures.

Extensive ulcerative lesions of GM in control animals developed 4 days after surgery. The mean area of ulcers in these rats was 44.9 mm² (24.4-91.0 mm²). Administration of Taftsin for 3 days significantly de-

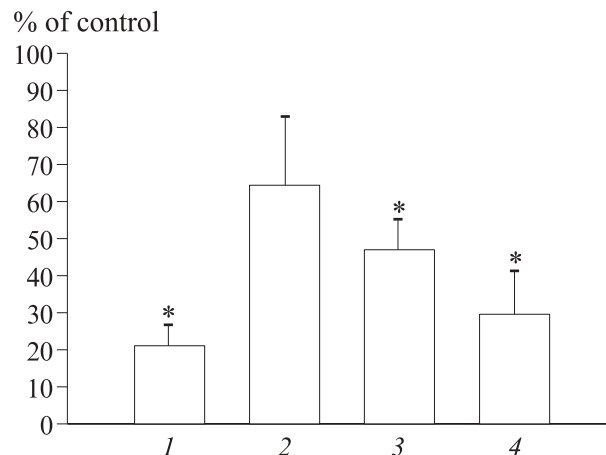


Fig. 1. Area of ulcerative lesions after intraperitoneal injection of Taftsin: ethanol ulceration (1); stress ulceration (2); and acetate ulceration, days 4 (3) and 7 (4). * $p < 0.05$ compared to the control (100%).

creased the area of ulcers compared to the control (19.3 mm²). These data show that chronic treatment with Taftsin had a protective antiulcer effect in animals with developing ulcers (Fig. 1).

On day 7 after surgery the area of ulcers in control rats decreased to 41.96 mm². Daily administration of Taftsin (4-6 days) to animals with developed ulcers significantly decreased the area of lesions to 10.6 mm² (Fig. 1).

Our results show that the endogenous immunostimulator Taftsin possesses antiulcer activity. The protective effect was observed after pretreatment with Taftsin 1 h before ethanol application and during chronic administration of the preparation to animals with developing acetate ulcers. Taftsin possessed therapeutic activity and accelerated healing of acetate ulcers. Taftsin had no effect on the central mechanisms of stress ulceration.

This work was supported by the Russian Foundation for Basic Research (grant No. 03-04-48664).

REFERENCES

1. I. P. Ashmarin, A. A. Kamenskii, L. A. Lyapina, *et al.*, *Vopr. Biol. Med.*, No. 1, 24-27 (2002).
2. I. P. Ashmarin, V. N. Nezavibat'ko, N. F. Myasoedov, *et al.*, *Zh. Vyssh. Nervn. Deyat.*, **47**, No. 2, 420-429 (1997).
3. A. A. Kamenskii, V. N. Kalikhevich, and N. Yu. Sarycheva, *Byull. Eksp. Biol. Med.*, **101**, No. 1, 55-57 (1986).
4. N. V. Kost, O. Yu. Sokolov, M. V. Gabaeva, *et al.*, *Bioorgan. Khim.*, **27**, No. 3, 180-183 (2001).
5. L. A. Lyapina, V. E. Pastorova, M. V. Kudashevskaya, *et al.*, *Byull. Eksp. Biol. Med.*, **116**, No. 5, 451-452 (1993).
6. S. B. Seredenin, M. M. Kozlovskaya, Yu. A. Blednov, *et al.*, *Zh. Vyssh. Nervn. Deyat.*, **48**, No. 1, 153-159 (1998).
7. L. P. Filaretova, A. A. Filaretov, and G. B. Makara, *Am. J. Physiol.*, **274**, G1024-G1030 (1998).
8. S. Okabe, J. Roth, and C. Pfeiffer, *Am. J. Dig. Dis.*, **16**, No. 3, 247-274 (1971).
9. I. Z. Siemion and A. Kluczyk, *Peptides*, **20**, 645-674 (1999).